Available online at www.sciencedirect.com
ScienceDirect
Medical Laser Application 23 (2008) 79–86
Medical Laser Application
www.elsevier.de/mla

Laser treatment of scars and keloids – How we do it

Carsten M. Philipp*, Dagmar Scharschmidt, H. Peter Berlien

Abteilung für Lasermedizin, Elisabeth Klinik Berlin, Lützowstraße 24-26, 10785 Berlin, Germany

Received 27 January 2008; accepted 30 January 2008

Abstract

The existence of scars may present considerable problems for patients. As well as being sometimes disfiguring and having an influence on a person's perception of him or herself, hypertrophic scars and keloids can often also cause pruritus, dysesthesia and pain, and can form strictures.

Since the first attempts to influence hypertrophic scars and keloids with lasers, many refinements in the technology and improved laser treatment techniques have taken place. Flashlamp-pumped dye lasers and near infrared (NIR) lasers are the most frequently used lasers for hypertrophic scar treatment, whereas CO_2 and Er:YAG lasers are preferred to diminish atrophic scars. Non-ablative skin remodeling may be used for minor changes.

Lasers and other intensive light sources can also play a role in prevention of scars, and new strategies for acne treatment are on the horizon.

Keywords: Keloid; Hypertrophic scar; Atrophic scar; Laser; LED; Acne

Introduction

In order to choose the right therapeutic option, a clear classification of scars is necessary, as different types of scars require different treatments. Both hypertrophic scars and keloids are raised and red, but where a hypertrophic scar remains within the confines of the original skin damage, a keloid grows beyond it. Also where a hypertrophic scar may flatten spontaneously during the course of one or more years, keloids remain elevated. Keloids appear most frequently in patients with darker skin types and are related to an inherited metabolic alteration in collagen, whereas hypertrophic scars are the result of increased collagen synthesis with a lack of collagen lysis during wound healing.

Atrophic scars are usually the result of primary inflammatory skin diseases such as acne and varicella. They are present as dermal depressions, which are caused by collagen destruction.

Treatment options

In the past, numerous modalities have been applied in scar treatment with differing results [1]. Especially the response of keloids is often unsatisfying and they may reoccur after therapy. Established treatments for scars or keloids are excisional surgery and cryotherapy, adjunctive intralesional steroid application, pressure therapy and covering with silicon gel sheets [2]. Fillers or punch excision are used for ice pick or atrophic scars.

*Corresponding author. Tel.: +49 30 2506915.
E-mail address: lasermed@elisabeth-klinik-berlin.de (C.M. Philipp).

1615-1615/$ - see front matter
doi:10.1016/j.mla.2008.01.005

Laser treatment of keloids

During the last few years, the flashlamp-pumped pulsed dye laser (FPDL) has been frequently used to treat keloids with promising results, in well-controlled studies [3]. But FPDL treatment alone is only suitable for smaller keloids with a limited volume. In larger keloids a combination of excision, corticoid application and FPDL treatment shows better results [4]. For highly proliferative or fibrotic keloids, we use various Nd:YAG-laser techniques to reduce vascularization and tissue masses.

Laser treatment of hypertrophic scars

FPDL treatment is an established technique, which is often used after failure of conservative treatment such as silicone tapes and compression. In some extended cases, transcutaneous use of Nd:YAG laser with ice cube cooling may be applied. Some residually pale and only slightly elevated hypertrophic scars may benefit from Er:YAG- or CO_2-laser ablation with additional sub-ablative thermal pulses [5].

Laser treatment of atrophic scars

Epidermal ablation with CO_2- or Er:YAG lasers are now established and efficient [6,7]. However, considerable side effects have led to a search for alternatives. Currently, the resulting solutions (non-ablative skin remodeling) are useful in mild atrophic scarring and esthetic procedures [8].

How we do it – choice of laser and technique

Clinical appearance of scars and keloids with their individual color, shape, size and vascularization varies within a wide range. Because of the very different clinical appearance, there is not only one laser, which is used for all different types of scars or keloids.

To choose the right system, it is imperative to categorize the type of scar properly and to determine which laser effect is desired (vascular, collagen). According to the different clinical appearance of scars, the correct laser type with its specific and characteristic tissue effect has to be chosen for the best treatment and most satisfying results. This may vary by using different treatment steps. Furthermore, the skin type of patients and the localization of the lesions also have to be considered (see Table 1).

Table 1. Choice of laser according to clinical features

Type	Clinical appearance	Laser and technique
Keloid	• Proliferative • Highly vascularized • Larger vessels • Large volume	Nd:YAG laser with ice cube cooling
	• Rigid • Little vascularization • Larger volume	Nd:YAG laser (interstitial vaporization)
Hypertrophic scar	• Erythematous • Capillary or telangiectatic vascularization • Less volume	FPDL with surface cooling
	• Non-proliferative • No visible vascularization • Mild hypertrophic	Non-ablative long pulsed IR lasers (1064, 1320 and 1450 nm)
Atrophic scar	• Saucer-shaped or ice pick indentions	Er:YAG laser; ablative/thermal CO_2 laser; pulsed/scanned

Table 2. Parameters for FPDL treatment of keloids and hypertrophic scars

Indication	Parameters	
Hypertrophic scars	Wavelength	585 nm
Burn scars	Energy	5–8 J/cm^2
Keloids	Spot size	10 mm
Erythematous	Exposition	0.5–2 ms
Strictures	Cooling	Cooling chamber

Hypertrophic scars and keloids: FPDL

The pulsed dye laser treatment of keloids and hypertrophic scars reduces microcirculation and leads to a reduction of erythema with lightening and significant alteration in texture, bulk and pliability of the skin. There are also positive effects with regard to pain and pruritus.

We usually apply FPDL at 585 nm, 0.5 or 2 ms, 5–8 J/cm^2 with surface cooling followed by 4–6 J/cm^2 without

Fig. 1. FPDL with cooling chamber during treatment of hypertrophic scar.

Fig. 2. Typical purpuric changes after FPDL treatment.

Fig. 3. Hypertrophic scar prior to FPDL treatment.

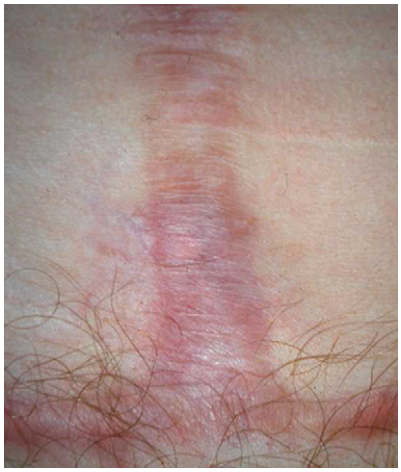

Fig. 4. Hypertrophic scar after six FPDL treatments.

Fig. 5. Hypertrophic scar prior to FPDL treatment.

Fig. 6. Hypertrophic scar after six FPDL treatments.

cooling, each at a spot size of 10 mm in a gently overlapping fashion (see Table 2).

In the case of an intense erythema, we prefer a continuous cooling of the skin surface using the cooling chamber, described in an earlier paper [9], to protect the superficial layer and allow compression of superficial vessels for increased light penetration (Fig. 1). Using the cooling chamber, thermal side effects at the epidermis, and a possible acute pain can be sufficiently reduced. Local anesthesia is not necessary in most cases or is sufficient using Emla cream or the cooling chamber alone.

A purpuric tissue response develops immediately after pulsed dye laser irradiation (Fig. 2), which disappears within 8–14 days. In a few cases, small bubbles or crusts develop in the treated area, which heals within a few days without intervention. Other rare side effects are hyperpigmentation or infection. The recurrence rate is very low and only seen in the treatment of proliferative keloids. Multiple treatments are required and the typical interval between treatments is 6–8 weeks. Most of the scars respond well and show a flattening, softening and a significant reduction of capillary perfusion (Figs. 3, 4 and 5, 6).

In some cases, it is necessary to remove a portion of the scar or keloid surgically, which is usually followed by additional steroid injections. After removal of the

sutures, FPDL treatment may be applied to the new scar formation.

Our results in early treatment with the argon laser [10] or more recently FPDL were promising and have led to a prevention of recurrences. People, who are also prone to develop hypertrophic scars and keloids or have a history of recurrences after other therapies, should be treated with the laser as early as possible after a surgical intervention to prevent new keloid formation. Silicone tapes or pads can be used during treatment intervals (after possible surface defects have healed).

Hypertrophic scars and keloids: Nd:YAG laser

Only limited success was achieved using FPDL treatment on prominent and fibrotic keloids and proliferative keloids. In these cases, a primary transcutaneous or interstitial Nd:YAG-laser treatment promises better results.

The effect on blood vessels is successfully used in the transcutaneous or interstitial Nd:YAG-laser treatment of hemangiomas and vascular malformations. The Nd:YAG laser damages deep dermal blood vessels without destroying the surrounding connective tissue [11,12]. Furthermore, a decreased collagen synthesis and unchanged collagenolytic activity has been observed, which indicates that the Nd:YAG laser would be successful in the treatment of hypertrophic scars and keloids.

Transcutaneous Nd:YAG-laser application

In the case of large and proliferating keloids, or if bigger vessels can be seen within the keloid using color coded duplex sonography, a transcutaneous Nd:YAG-laser application is used. The treatment is painful and requires local or general anesthesia.

For transcutaneous application the used power is 40 W or more in continuous wave or chopped mode (see Table 3). The power used depends on color of the keloids. The more erythemateous the keloid is, the lower the power. The laser is applied with a spot size of 3–4 mm through an ice cube keeping it in close contact with the tissue to reduce thermal effects at the surface (Fig. 7). As the laser penetrates much deeper than the thermal cooling effect, a heating of vessels (strong) and collagen (mild) occurs. As with the cuvette system, the ice cube allows compression of the tissues. The ice cube has to be clear and without inclusions of air or dirt to guarantee sufficient laser light transmission as well as less scattering and absorption. Cracked or partially melted ice cubes have to be replaced immediately.

Coagulation or blanching of the surface should be avoided because of a higher risk of thermal necrosis development. Monitoring is mostly visual; hence, the quality of the ice cubes is of major importance. The most important indication of a sufficient dose is a longer reperfusion time. Permanent color changes, lighter or darker indicate overtreatment and must be avoided. After treatment, the keloid develops a glassy and swollen appearance reaching its maximum at 24 h after treatment, and returning to normal within a week.

Table 3. Parameters for transcutaneous Nd:YAG-laser treatment of keloids and hypertrophic scars

Indication	Parameters	
Proliferative keloids	Wavelength	1064 nm
Deeper, larger vessels	Power	40–50 W
	Spot size	3–4 mm
	Exposition	cw or chopped
	Cooling	Continuous ice cube cooling

Fig. 7. Nd:YAG laser with ice cube cooling, application on a keloid.

Side effects are swelling, induration and development of small bubbles or crusts. The risk of thermal damage followed by necrosis is low if blanching is avoided.

The result of the irradiation can be judged at the earliest after 6–8 weeks. Usually, some shrinkage and lightening is observed caused by the reduction of nutritive vessels. The result is a stop of growth, a lightening and a reduction in size. Also pain and pruritus are generally reduced. There is no complete reduction in size with this method. In total, 5–8 sessions are necessary to reach significant results and the interval between the treatments is 8–10 weeks.

We recommend ice packs for post-treatment care following this non-ablative application and the use of only a greasy ointment, for example with petrolatum. The patients should avoid intense sun exposure for 6–8 weeks and mechanical irritation of the treated area. Wound dressing and antibiotic or antiviral medications or creams should be restrictively used (individual history). The patients can wash the area carefully with mild soap or have a shower. Bathing or swimming is not allowed.

Interstitial Nd:YAG – ITT vaporization

Distinct and rigid, pale keloids with a diameter of 1 cm or more can be treated by interstitial Nd:YAG-laser vaporization. Using this technique, a reduction of the scar dimensions is possible by vaporization of the inner keloid fibroid masses without epidermal injury. We also applied this technique to some erythematous and proliferative keloids, in cases where transcutaneous Nd:YAG-laser treatment and surgical mass reduction were not applicable.

Interstitial Nd:YAG-laser therapy is painful and local or general anesthesia is necessary.

With this technique, a 400 or 600 μm laser bare fiber is positioned in the center of the lesion by means of an i.v.-line device. The position of the bare fiber can be controlled by ultrasound or the position can be nearly located with the laser pilot beam (Fig. 8). Under continuous digital control of the skin surface temperature, the inner part of the keloid tissue is vaporized using

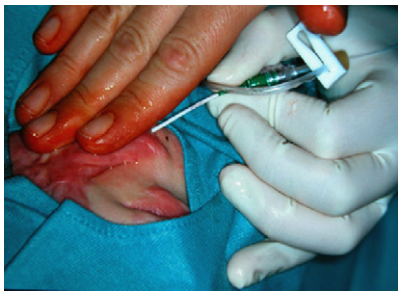

Fig. 8. Interstitial Nd:YAG-laser vaporization in a keloid.

Table 4. Indications and parameters for interstitial Nd:YAG-laser treatment

Indication	Parameters	
Larger fibrotic and non-proliferating keloids (> 1 cm diameter)	Wavelength Power Exposition	1064 nm 30–35 W 0.1–0.3 s/ chopped

Fig. 9. Burn keloid prior to treatment.

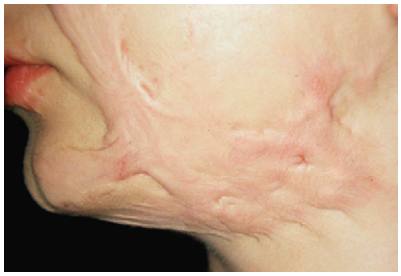

Fig. 10. Keloid after two interstitial and eight transcutaneous Nd:YAG-laser applications.

Fig. 11. Atrophic scars before (left) and 6 months after (right) one CO_2- laser ablative procedure.

Fig. 12. Scanned CO_2-laser vaporization of atrophic acne scars.

Fig. 13. Removing dried tissues between the passes (CO_2- and Er:YAG-laser resurfacing).

30–35 W in chopped mode or using continuous wave in combination with slow retraction of the system (see Table 4). The speed of the retraction depends on the temperature of the skin. If keloid extension is massive, multiple non-overlapping punctures can be performed during one operation. Normal reactions after therapy are a swelling and induration.

Side effects of this technique are more frequent and severe than with FPDL, and occur more frequently than with transcutaneous Nd:YAG-laser treatment with ice cube cooling.

Despite measures to control the skin temperature, the development of small thermal injuries is still possible. We recommend an immediate cooling with ice cubes after palpation or observation of thermal skin damage. Should irreversible thermal damage occur, it presents the risk of necrosis and the recurrence or possible worsening of the condition. Another risk that should be mentioned is infection. The interstitial laser treatment requires considerable experience of the physician. The result of the treatment with this method can be easily destroyed by "overtreatment" or "undertreatment".

Using interstitial Nd:YAG-laser vaporization, shrinking and flattening of thick and extremely rigid keloids can be achieved, in addition to an improvement in the color and a reduction of pain or pruritus. A complete regression of the keloid size is not possible. Treatment can be repeated after 8–10 weeks if necessary. Once sufficient reduction of the keloid size has been reached, additional transcutaneous Nd:YAG or FPDL treatment can be used to obtain a further improvement together with scar reduction in erythematous lesions (Figs. 9 and 10).

Atrophic scars: CO_2- or Er:YAG laser (ablative treatment)

We mainly use the CO_2 laser in the treatment of atrophic acne scars, but pulse modulated Er:YAG lasers with thermal mode options are quite similar. Because of a high risk for recurrence or worsening, we do not use either of the above lasers for treatment of keloids.

High-energy pulsed or scanned CO_2-, or Er:YAG laser systems allow controlled superficial vaporization of thin epidermal layers with controlled thermal damage to sub-cutaneous collagen. This results in epithelial regrowth and collagen induction, leading to a smoothing of the skin texture and skin surface marks (Fig. 11). Different investigations show equivalent clinical results for pulsed or scanned systems.

We work with a continuous wave CO_2 laser with an attached microprocessor-controlled scanner to ensure that the radiation "dwell" time (the time it takes the tissue to cool to 50% of its peak power temperature) is less than 1 ms. Charred and dried tissues are removed with wet gauze between the passes (Figs. 12 and 13). We use a power of 10–15 W and the radiation time at any given point of the focussed beam is 500 μs by moving in different geometric pattern (see Table 5).

Table 5. Parameters for atrophic scar treatment with CO_2- and Er:YAG lasers

Indication	Parameters	
Atrophic scars	*CO_2 laser*	
Saucer-shaped ice	Wavelength	10,600 nm
Pick indentions	Power	10–15 W
(limited)	Exposition	Scanned/pulsed
	Local exposure	500 μs
	Er: YAG laser	
	Wavelength	2940 nm
	Energy per pulse	5–25 J/cm^2
	Spot size	5 mm
	Local exposure	250 μs (+ dwell time)

In most cases, a topical anesthesia with Emla cream or local or regional anesthesia is sufficient. General anesthesia is only recommended for larger areas.

For post-treatment, we prefer an open technique with a petrolatum ointment and the application of cold black tea compresses 5–8 times a day. Alternatively, semi-occlusive dressing (polyurethane, hydrogels) and cooling packs are used.

Sun protection or sun avoidance for up to 4 months is recommended to minimize the risk of hyperpigmentation. We recommend an antibiotic medication only for treatment of the full face and an antiviral medication only in case of a medical history requires this. If hyperpigmentation is observed, patients can be treated with azelaic acid or hydroquinone containing products.

Side effects after therapy are an edema and swelling, serious wound oozing and the development of crusts. Complete re-epithelization takes 7–10 days. The ensuing erythema disappears within 6–8 weeks. Complications at the acute phase are wound infection, at a later phase, a prolonged erythema or hyperpigmentation. Rare side effects are hypopigmentation or worsening of the condition. In partial face treatments, it is mandatory to comply with the esthetic units of the face.

Atrophic scars: NIR laser (non-ablative treatment)

Side effects and risks of ablative scar treatment have encouraged the search for alternative and less invasive methods to treat atrophic scars. Current systems are based on deep penetrating pulsed Nd:YAG (1064 and

1320 nm) or diode laser (1450 nm) with applicators with integrated cooling devices. Collagen changes in the dermis are responsible for a change in the skin texture, but treatment requires multiple applications over a period of about 6–12 months. Changes are mild and more pronounced for mild wrinkles than for atrophic scars e.g. acne scars [8]. Recent developments also use radiofrequency or fractionated laser application [13,14].

Discussion

No therapy can remove scars completely, but the discerning use of lasers helps to relieve patients of related symptoms. Itching, painful dysesthesia, strictures and hypertrophia can be reduced or removed with laser treatment. Despite surgical revision, steroid or 5-Fluorouracil injections and conservative treatments such as compression and silicon dressings are effective in many hypertrophic scars and keloids, there are a certain number of patients that need additional treatment. A successful treatment is based on clinical findings and the type of scar. In proliferative and large keloids, it usually leads to a step program that combines the invasive and less invasive treatments mentioned.

FPDL treatment of hypertrophic scars and smaller keloids significantly improves most of the symptoms. It is suitable for burn scars as well as for surgical scars. As complications are rare and side effects mild, it could be considered to be the second option after silicon dressing of any surgical wound that shows incipient hyperproliferation.

While mild cases of atrophic scarring may benefit from new techniques such as non-ablative skin remodeling with pulsed near infrared (NIR) lasers, the more pronounced lesions require an ablative technique. CO_2 lasers and Er:YAG lasers in thermal mode have proven to be equivalent in effectiveness and procedural safety for removal or flattening atrophic scars. Pronounced side effects and the need for intensive wound care restrict this technique.

New techniques have been available since 2006. Other than the usual full surface procedures, Fraxel^{TM} affects only a fraction of the skin at a time with multiple microscopic laser spots placed randomly and sequentially. The first results have been promising and the side effects are significantly reduced but also in this scar type, a combination with other methods, e.g. fillers or punch excisional therapy will lead to best results.

Most atrophic scars seen in our department are caused by acne. Recent studies show that photodynamic therapy with "endogenous" photosensitizers derived from 5-ALA (produced by bacteria) is effective in the treatment of active acne and helps to prevent scar formation [15]. Other light devices (red- or NIR-LEDs) may improve wound healing in general.

Zusammenfassung

Laserbehandlung von Narben und Keloiden – Unser Behandlungskonzept

Narben können Patienten erhebliche Probleme bereiten. Neben der manchmal entstellenden Wirkung können sie zu Juckreiz, Dysaesthesien und Schmerzen führen oder durch Kontrakturen die Bewegung einschränken.

Seit den ersten Laserbehandlungen sind durch technologische Verbesserungen sowie eine verbesserte Technik der Anwendung deutliche Fortschritte erreicht worden. Blitzlampen-gepumpte Farbstofflaser und Nahinfrarot (NIR)-Laser sind heute in der Behandlung hypertropher Narben und Keloiden am weitesten verbreitet. CO_2- und Erbium:YAG-Laser werden zur Behandlung von atrophen Narben genutzt. Nicht ablative Verfahren können bei weniger ausgeprägten Veränderungen genutzt werden.

Laser und andere intensive Lichtquellen spielen heute auch eine Rolle in der Vorbeugung von Narben und als therapeutische Option in der Behandlung der floriden Akne.

Schlüsselwörter: Keloid; Hypertrophe Narbe; Atrophe Narbe; Laser; LED; Akne

References

[1] Berman B, Bieley HC. Keloids. J Am Acad Dermatol 1995;33(1):117–23.

[2] Ohmori S. Effectiveness of silastic sheet coverage in the treatment of scar keloid (hypertrophic scar). Aesthet Plast Surg 1988;12(2):95–9.

[3] Dierickx C, Goldmann MP, Fitzpatrick RE. Laser treatment of erythematous/hypertrophic and pigmented scars in 26 patients. Plast Reconstr Surg 1995;95(1):84–90.

[4] Alster TS. Laser scar revision: comparison study of 585 nm pulsed dye laser with and without intralesional corticosteroids. Dermatol Surg 2003;29(1):25–9.

[5] Scharschmidt D, Algermissen B, Philipp C, Berlien HP. Prinzipien der Laserbehandlung von Narben und Keloiden. J DGPW 1998;16:7–9.

[6] Bernstein LJ, Kauvar AN, Grossman MC, Geronemus RG. Scar resurfacing with high-energy, short-pulsed and flashscanning carbon dioxide lasers. Dermatol Surg 1998;24(1):101–7.

[7] Tanzi EL, Alster TS. Treatment of atrophic facial acne scars with a dual-mode Er:YAG laser. Dermatol Surg 2002;28(7):551–5.

[8] Rogachefsky AS, Hussain M, Goldberg DJ. Atrophic and a mixed pattern of acne scars improved with a 1320 nm Nd:YAG laser. Dermatol Surg 2003;29(9):904–8.
[9] Sokoll C, Philipp C, Berlien HP. Behandlung von Besenreisern mit einer neuen Kühlküvette. Lasermedizin 1995;11:131–8.
[10] Kuhls R, Bier J, Berlien HP. Behandlung von hypertrophen Narben bzw. Keloiden durch zentrale Exzision mit anschließender postoperativer, prophylaktischer Argon-Laser-Bestrahlung – Ergebnisse einer präliminären Studie. Lasermedizin 1995;11:67–72.
[11] Philipp CM, Poetke M, Berlien HP, Engel-Murke F, Waldschmidt J. Treatment of congenital vascular disorders: classification, step program, and therapeutic procedures. SPIE Proc 1994;2086:228–37.
[12] Poetke M, Philipp CM, Urban P, Berlien HP. Laser therapy of haemangiomas and vascular malformations – techniques and strategies. Med Laser Appl 2004; 19(1):32–44.
[13] Ruiz-Esparza J, Gomez JB. Nonablative radiofrequency for active *Acne vulgaris*: the use of deep dermal heat in the treatment of moderate to severe active *Acne vulgaris* (thermotherapy): a report of 22 patients. Dermatol Surg 2003;29(4):333–9.
[14] Alster TS, Tanzi EL, Lazarus M. The use of fractional laser photothermolysis for the treatment of atrophic scars. Dermatol Surg 2007;33(3):295–9.
[15] Taub AF. Photodynamic therapy for the treatment of acne: a pilot study. J Drugs Dermatol 2004;3(Suppl. 6): S10–4.